

D E N T A L P R A C T I C E

Advantages and Disadvantages of Direct Gold Restorations

LAWRENCE L CLARK

Whenever we speak of the advantages of direct gold for restorations the quotes go back as far as G V Black. Standard replies to the question of advantages are: it is conservative; it is durable; it is kind to the tissues; it has the finest margins. Perhaps some other advantages to consider are those that would interest dental students. For example, direct gold: (1) can be handled by any student that wishes to perform a good service; (2) exposes students to excellence; (3) fine tunes the manual dexterity of the dental student; (4) can be placed using hand pressure, when powdered

gold is used, with little or no pulpal insult; (5) allows the operator to attain the self-satisfaction for which all strive as a reward for our efforts. We can show the students how useful direct gold can be for repairing carious crowns or abutments (Fig 1) and how satisfying it is to see a mo-

University of Mississippi, School of Dentistry,
General Practice Residency, 2500 North
State Street, Jackson, MI 39216-4505

LAWRENCE L CLARK, DDS, MS, associate
professor of restorative dentistry and director,
General Practice Residency

From a symposium "Why Bother Continuing to Use an Outdated Restorative Material like Direct Gold?" presented at the annual meeting of the American Academy of Gold Foil Operators, 19 October 1984, in Atlanta

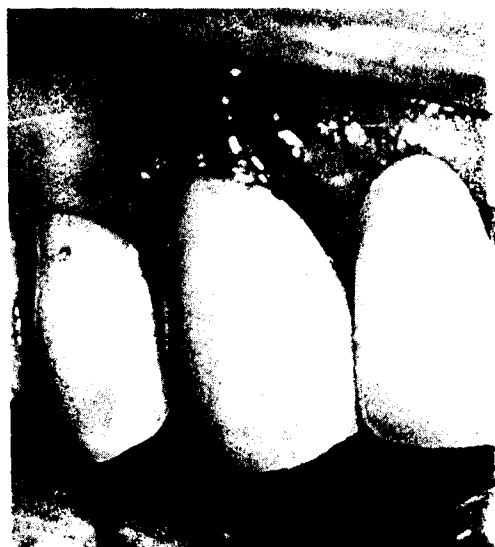

FIG 1. Canine abutment—class 5; caries restoration with direct gold

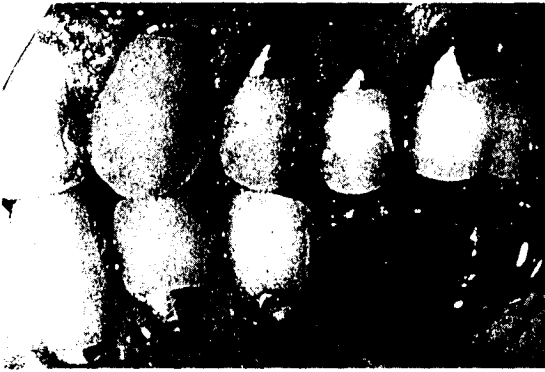


FIG 2. Six direct gold restorations and one amalgam (direct gold by Capt Glenn E Gordon, DC, USN)

that has been restored with this material (Fig 2).

The statement by Hollenback (1962) about taking a conservative approach in dentistry and ultimately giving a better service is an advantage that we rarely discuss with nonbelievers. We do not rebut our critics with the advantages of the sterility of gold foil and its antibacterial action (Smith, 1957); or the histological evidence of the minimal effect on the pulp by the condensation of gold foil (Thomas, Stanley & Gilmore, 1969).

Certainly, no one disagrees with these statements. However, maybe we should spend more time on the advantages that seem to concern most dentists today, **Time and Money**. Ingraham and Koser (1961) mentioned in the introduction to their text that "Gold foil can become one of the most practical, profitable and pleasurable parts of a dental practice." As you think about that quotation, I want you to try to remember if anyone ever mentioned it during your school years. Why don't we tell our colleagues how practical direct gold restorations are in a general practice? Why don't we emphasize the one-visit restoration with the finest material available in dentistry? Why don't we talk about the amount of money that can be made placing direct gold restorations? Most of all, why don't we talk about how great it feels to place a good direct gold restoration? If I had to answer these questions it would be difficult, because I didn't grow up in the marketplace of dental economics where everything is a commodity.

The advantages of direct gold are many but

the use is little. Are the disadvantages of the restoration more than we care to admit? After all, it has been said that beauty is in the eyes of the beholder; maybe we have tunnel vision.

Let's consider some of the disadvantages of the gold foil restoration. According to Coy (1957) there are only three minor disadvantages: color, thermal conductivity, and difficulty of manipulation. If these are the only disadvantages then why are fewer and fewer gold foil restorations being placed? Some dentists say that with the cost of gold today the restoration is not economical to accomplish. Stibbs (1980) says that this is not true, even if the cost of gold were to reach \$700 an ounce. Others say that esthetics is a big concern and therefore color is a major disadvantage and not a minor one. Certainly we can agree that esthetics is important, but we must admit that it is not a reason to bury gold foil completely. Many incipient occlusal lesions and pits, on adults and adolescents, can be restored with foil and still leave an esthetic appearance. Class 3 lesions can be restored by means of a lingual approach and not change the esthetics (Fig 3). Also, class 5




FIG 3. Class 3 direct gold restoration on the mesio-lingual of the maxillary right central incisor—lingual view




FIG 3A. Facial view

lesions that are minimal can be kept conservative and esthetically acceptable (Fig 4).

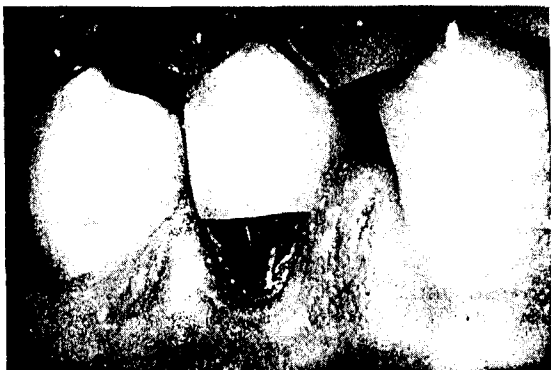

FIG 4. *Class 5 direct gold restoration on the mandibular right first premolar*

As I continue to think about it, I have difficulty understanding why these few so-called disadvantages are placing the gold foil restoration among the obsolete. Maybe there is another reason. Maybe we have overlooked the biggest disadvantage of the gold foil restoration. "Ourselves."

For years, before my dental career as well as after, the gold foil restoration was placed on a pedestal of excellence that only a few could reach. When gold foil was discussed by our dental materials teachers they always made it a point to tell you how technic sensitive it was and that there was nothing worse than a poorly placed gold foil restoration. We would condense our foil into a cavity prepared in an ivory block, finish and polish it, and then cut it out so we could see all of our faults; not so we could see what was good, only what was bad. Then we would move on to our course in operative dentistry. Here we learned the Black's, Ferrier's, and Woodbury's preparations, which in the early days were by no means conservative. Now I'm not saying that conservative preparations weren't being used in the early 1960s; I am saying, however, that they weren't being taught out of dental school textbooks. Dental schools were teaching the larger preparations with acute angles and minimal retention.

How many times, while you were in school, did that triangular bar take you an hour or more to get started? Then halfway through your con-

densation, due to a slight misdirection of your condenser, everything you had placed came out. This never happened to you? You were either very lucky or very good. Most students lived in fear of placing any gold foil beyond a pit or small class 1 occlusal. It seemed as if every instructor was waiting for you to place a class 3 or class 5 gold foil, just so he could find porosity or try to pull the restoration out of the cavity. The gold foil restoration became the measure of your ability as an operative dentist. Although you wanted to be a good operative dentist, you would always worry when your schedule showed a foil patient coming up. There was no enjoyment on that day.

I don't want to give you the impression that I wasn't taught the principles and techniques of direct gold. We all were taught and we all performed the necessary procedures for graduation. It just wasn't fun and we had no incentive to continue using direct gold.

Now we all know that some of our classmates never had a single problem with a gold foil restoration and enjoyed every one that was done. I envy them. I didn't start enjoying gold foil until my residency years, when requirements weren't the priority, designs of cavities were changing from what I had been taught and I was my worst critic. However, even at that time I still had the feeling that I didn't have the right to use gold foil because I wasn't good enough. To be honest, there are times when I still feel that I am out of my class. That is the point I am trying to make when I say that we should consider "Ourselves" under disadvantages. Grainger (1971) said that our young people need models of what man at his best can be. I agree models are necessary, but I am afraid that what we have had, instead, are idols. Idols are a disadvantage, because the student never feels as if he or she can reach that level and consequently the result is frustration and aversion.

Miller (1974) said that the problem today is lazy and apathetic faculty that aren't competent in gold foil. This is true, but where did this faculty get that attitude? Was it from "Ourselves"? Did we perform for these people when they were in school, instead of teach? Did we tell them how difficult it was to accomplish this finest of restorations? Did we unwittingly discourage them from pursuing excellence in operative dentistry? Wolcott (1974) said that

the school and teachers are responsible for these catastrophic deficiencies in our newly graduated professionals, because they certainly would not choose deliberately to abandon their integrity and self-destruct by poor performance. No, instead they choose not to place gold foil restorations, and become critics as a defense for not using gold foil.

By now, some of you are wondering how I can make these accusations. Well, I would like to give one more example of "Ourselves" as a disadvantage. We all remember when powdered gold came into this country and Drs Baum and Lund worked so hard to get it accepted as a direct gold restorative material. Powdered gold was easier to handle than gold foil, was inherently cohesive, could be condensed by hand pressure, had greater density than gold foil, and gave restorations that were harder than gold foil (Lund & Baum, 1963). Richter and Cantwell (1965) said that powdered gold had kindled renewed interest in


cohesive gold restorations and they caused less trauma while being placed in less time. Here we had an opportunity to further the direct gold restoration through the use of powdered gold. What did we do? Many of us fought this advancement and even came out vocally against its use. Even today we still have schools that do not teach the use of powdered gold or the Loma Linda designs of cavities. Of course we have many schools that do not teach any gold foil, so maybe I shouldn't be too critical. But I am afraid that if we continue to resist good changes then direct gold as a restorative material will become outdated.

We must take a good look at ourselves and re-evaluate our positions. Do we want to be role models or idols? Do we want the gold foil restoration replaced by the composite materials, so that mediocrity can replace excellence? Do we want this to be the future of dentistry? (Figs 5 & 6)

If we are going to make an effort to preserve

THE SYNCHRONIZED SYSTEM

WHICH POSTERIOR RESTORATIVE WOULD YOU STAKE YOUR REPUTATION ON?




Endurance... **Confidence**... **Intense Cure**... **Three Shocks**...

DenMat

FIG 5. Wouldn't you rather stake your reputation on direct gold?

MARATHON



Endurance... **Confidence**... **Intense Cure**... **Three Shocks**...

DenMat

FIG 6. No restoration is more durable than direct gold.

and encourage the use of direct gold as a restorative procedure we need to do much more in this wonderful world of marketing. I don't know if you realize how distasteful the word 'marketing' is to me, but since we have been blessed with it by a past-president of the American Dental Association, I guess we have to live with it.

When was the last time you saw an article on direct gold restorations in a "popular" journal? By popular I mean journals such as the *Journal of the American Dental Association*, the *Journal of the Academy of General Dentistry*, and the new *Compendium of Continuing Education*. The journals to which we always submitted our articles are the *Journal of the American Academy of Gold Foil Operators*, the *Journal of Prosthetic Dentistry*, and *Operative Dentistry*. Although these journals are among the most credible, we did not get our message to the majority, only to those who already believed. Today, we need to publish more than ever before and get our message to all of our colleagues. Let's write for the *Journal of the American Dental Association*, the *Journal of the Academy of General Dentistry*, the *Compendium of Continuing Education*, and state journals, and tell everyone how easy it is to place direct gold and how rewarding it is from the standpoint of both economics and satisfaction. We need to present a positive image for all to see.

Let's take a final look at "Ourselves," and if we are a disadvantage then it's time for a change. Knowledge is the power we have to perpetuate quality in dentistry. If we do not use it soon the gold foil restoration will be no more than a chapter in dental history (Fig 7).

References

- COY, H D (1957) The selection and purpose of dental restorative materials in operative dentistry *Dental Clinics of North America* March 65-80.
- GRAINGER, D A (1971) Gold foil—its future in dental education and state boards *Journal of the American Academy of Gold Foil Operators* 14 77-88.

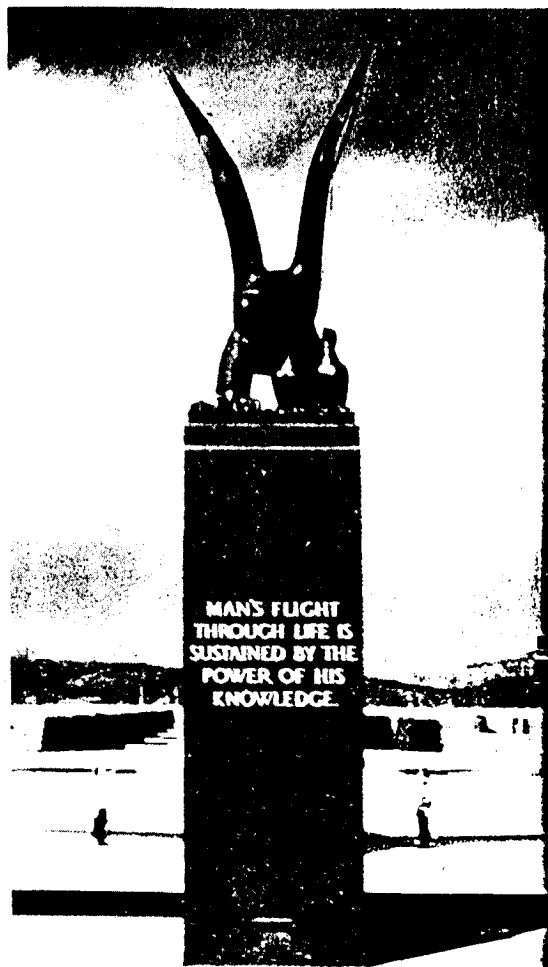


FIG 7. This monument is at the US Air Force Academy in Colorado Springs, Colorado.

- HOLLENBACK, G M (1962) A plea for a more conservative approach in certain dental procedures *Journal of the Alabama Dental Association* 46 16-19.
- INGRAHAM, R & KOSER, J R (1961) *An Atlas of Gold Foil and Rubber Dam Procedures*. Buena Park, Calif: Uni-Tro College Press.
- LUND, M R & BAUM, L (1963) Powdered gold as a restorative material *Journal of Prosthetic Dentistry* 13 1151-1159.
- MILLER, C H (1974) Troublesome trends in

dentistry *Journal of the American Academy of Gold Foil Operators* **17** 11-16.

RICHTER, W A & CANTWELL, K R (1965) A study of cohesive gold *Journal of Prosthetic Dentistry* **15** 722-731.

SMITH, B B (1957) Gold foil in everyday practice *Dental Clinics of North America* March 123-137.

STIBBS, G D (1980) Direct golds in dental res-

torative therapy *Operative Dentistry* **5** 107-114.

THOMAS, J J, STANLEY, H R & GILMORE, H W (1969) Effects of gold condensation on human dental pulp *Journal of the American Dental Association* **78** 788-794.

WOLCOTT, R B (1974) Times for change *Journal of the American Academy of Gold Foil Operators* **17** 9-10.