

Mat gold foil with a veneer cohesive gold foil surface for Class V restorations

*John R. Koser, D.D.S., Los Angeles, and
Rex Ingraham, D.D.S., Hollywood, Calif.*

Placement of Class V gold foil restorations in the gingival area should not be considered a specialized procedure today. A knowledge of the requirements of cavity preparation, and the acquisition of skill in the manipulation of gold foil and in the finishing of the restoration enables the dentist to provide his patients with a superior health service.

The diagnosis and treatment of conditions of the dentition should not be determined by the operator's ability or lack of ability to perform a particular operation. The patient's welfare should determine the choice of restorative material and the procedure to be followed in each instance. The restoration of gingival surfaces attacked by dental caries and erosion is a constant problem to every general dental practitioner. The use of amalgam, siliceous cements and the newer plastic materials leaves a great deal to be desired in the treatment of these conditions. The permanency, tissue tolerance, and esthetic results of each of these materials can be challenged.

It is not, however, the purpose of this paper to discuss the advantages of gold foil as a restorative material, but rather to offer a simplified procedure that will overcome the prejudices against its use. The most common objections to the use

of gold foil have been the tediousness of gold foil procedures, the discomfort to the patient as well as possible traumatic injury.

Development of the new "mat-cohesive" technic for the placement of Class V gold foil restorations has, to a large extent, eliminated these objectionable factors. Three fourths to four fifths of a Class V prepared cavity can be filled with a core of mat gold foil in a matter of minutes. It is easily swedged into the retentive portions of the cavity with hand pressure. The only mechanical condensation required in this technic is the recondensation of mat foil into the retentive portions of the cavity and the stepping of cohesive foil over the surface of the mat foil. This veneer of cohesive gold provides a protective layer over the mat foil core and seals the surrounding cavosurface margins of the preparation. It is possible to place ideal restorations of much greater size in gingival cavities in less time and with a minimum of trauma when the "mat-cohesive" technic is employed.

Presented as part of a symposium, "Selection and Use of the Available Restorative Materials" before the Section on Operative Dentistry, ninety-sixth annual session, American Dental Association, San Francisco, October 19, 1955.

COMPARISON OF PHYSICAL PROPERTIES

Mat gold foil differs from the so-called cohesive type foils. It is a fine, electrolytic, crystalline deposit made adhesive by the nature of its finely divided crystalline structure and by the extremely pure state of the metal itself. Its mechanical strength is the result of a special molding and heat treatment process. This property renders it easier to manipulate. Because mat gold foil is highly adhesive and cohesive, and because it is more readily adaptable than other types of foil, it is ideally suited for building up the internal bulk of Class V, Class I and the occlusal portion of Class II restorations. Hand instruments of proper size and shape should be employed. The best results have been obtained when using hatchet and hoe type parallelogram condensers. The face of these instruments is 1 mm. long and .6 mm. wide and is slightly rounded at the edges to prevent tearing of the foil and to permit the instrument to be used in a rocking motion. A modified Royce type of serration is preferable. A thumb and finger stop on the shank allows maximum finger pressure during condensation (Fig. 1).

Mat foil should not be used on the surface of restorations. Its crystalline-like structure apparently does not weld into as homogeneous a mass as cohesive type golds, therefore, there is a greater tendency to surface pitting. This undesirable quality of mat foil is eliminated by surfacing it with a veneer of cohesive gold foil. A cohesive gold foil surface, when properly condensed, will resist pitting and will receive and maintain a high polish ideal for tissue tolerance.

HIGHER FREQUENCY WELDING OF GOLD FOIL

Both laboratory research and clinical investigation have indicated definite advantages to the welding of cohesive type

gold foil by means of high frequency vibrations with very low magnitude. All dentists are familiar with the present methods of condensation in which either hand malleting or the low frequency mechanical condenser is employed. The present malleting methods using 360 vibrations per minute or less, require considerable magnitude of the blow for adequate condensation of the foil. Investigations indicate that vibrations of approximately 3,600 cycles per minute with very low magnitude will accomplish the same condensation and weld of gold foil as the present methods without resultant traumatic discomfort to the patient or unfavorable postoperative symptoms.

Knoop values have been determined for specimens of gold foil welded by both methods. Specimens nos. 1, 2 and 3 were condensed with the pneumatic type condenser adjusted to its maximum frequency (360 vibrations per minute) and magnitude of blow (see table). Specimens nos. 4, 5 and 6 were welded at approximately 3,600 vibrations per minute with very low magnitude. By comparison, the average Knoop value of the specimens welded by the new high frequency technic is slightly higher than the average hardness of those condensed at the familiar low frequency. This indicates that the magnitude of the blow bears an inverse relationship to the frequency of the blow.

One of the most apparent advantages of this method of condensation is the highly favorable reaction of the patient during placement of the foil. Elimination of the hand mallet and mechanical condenser alleviates patient discomfort during the operation. Every restoration should be placed with as much care and consideration and safeguarding of vital tissue as is commensurate with practical procedure.

Adaptation and seal of the fragile cavosurface margins of the cavity without damaging enamel or cementum have al-

ways required the utmost skill of the operator. By employing only the lightest touch with the high frequency condenser point, foil can be adapted against surrounding walls without danger of damaging the cavity margins. After sufficiently banking foil against the cavo-surface angles of the cavity, more finger pressure may then be exerted to insure adequate density of the foil sealing the margins. Foil also can be laid down on the surface of the restoration with much greater rapidity than with the present methods of condensation.

The initial studies of this technic have been accomplished with experimental

apparatus. An electronic unit is under development which has been tested for versatility and dependability. Both frequency and magnitude are manually controlled in this unit by means of variable resistors. Condensation by higher frequency produces principally a surface welding of the foil. For this reason, it has been found necessary to employ a blow of lower frequency with increased magnitude when swedging a bulk of mat foil into the retentive portions of the cavity.

A dry field is essential for the proper placement of gold foil as well as for any other restorative material. With little experience, the practitioner can obtain iso-

Table • Left: Knoop values for specimens 1, 2, 3 condensed with mechanical condenser, 360 vibrations per minute, high magnitude of blow. Right: Knoop values for specimens 4, 5, 6 condensed with high frequency condenser, 3,600 vibrations per minute, very low magnitude of blow

| | |
|---|---|
| Specimen 1 | Specimen 4 |
| 100 Gm. Knoop | 100 Gm. Knoop |
| Test A, 319 F.U. | Test A, 314 F.U. |
| B, 305 F.U. | B, 292 F.U. |
| C, 311 F.U. | C, 307 F.U. |
| D, 310 F.U. | D, 343 F.U. |
| E, 298 F.U. | E, 321 F.U. |
| Specimen 2 | Specimen 5 |
| 100 Gm. Knoop | 100 Gm. Knoop |
| Test A, 312 F.U. | Test A, 293 F.U. |
| B, 301 F.U. | B, 303 F.U. |
| C, 298 F.U. | C, 319 F.U. |
| D, 293 F.U. | D, 312 F.U. |
| E, 311 F.U. | E, 309 F.U. |
| Specimen 3 | Specimen 6 |
| 100 Gm. Knoop | 100 Gm. Knoop |
| Test A, 310 F.U. | Test A, 293 F.U. |
| B, 296 F.U. | B, 340 F.U. |
| C, 299 F.U. | C, 306 F.U. |
| D, 304 F.U. | D, 312 F.U. |
| E, 307 F.U. | E, 319 F.U. |
| 304.9 Average for low frequency, high magnitude method | 312.2 Average for high frequency, low magnitude method |

Note: F.U. refers to "filar units." A 10.25 mm. lens was used in examining each specimen.

lation of the area and a clear field of operation quickly and efficiently through application of the rubber dam. Only lack of experience with rubber dam technic can create an aversion to its use. Any dentist willing to force himself to the initial use of the rubber dam soon will be convinced of its value as a timesaver and as a method by which he can obtain superior results with less effort.

CAVITY DESIGN

Design of the Class V cavity for the reception of gold foil is simple. Proper application of the rubber dam and careful retraction of the gingival tissue by a cervical clamp provide an excellent field of operation with adequate room for placement of the gingival wall under the protection of the free margin of the gingiva (Fig. 2). The position of the retracted septum is an excellent guide for determining the extensions of the mesial and distal walls of the cavity. These walls normally extend to, or lie beyond, the angles of the tooth and are placed under the protection of the free gingival tissue to prevent recurrence of caries at the margins of the cavity. The incisal or occlusal wall is carried to the height of the cervical contour of the crown. The outline form of this wall can be developed to harmonize with tooth form and with the plane of the occlusion remarkably well. The presence of erosion, decalcification or tissue recession influences the extensions of the Class V cavity outline form.

Common variations in outline form are illustrated in Figure 3.¹ A illustrates a straight incisal or occlusal margin which is indicated where there has been considerable destruction of enamel tooth surface in the cervical region. B shows a curved incisal or occlusal margin which produces a more harmonious outline form and allows for greater conservation of labial and buccal

tooth surfaces. C indicates that where gingival erosions extend into interproximal embrasures, cavity outline must be extended to include these regions. D shows that where lines of decalcification follow the crest of the gingiva, box forms must be extended in the direction of contact points to include them.

Retention for the foil is obtained by placing a slight undercut just within the dentin of the occlusal and gingival walls (Fig. 4). If the incisal or occlusal wall is undercut too much, the cavosurface angle of the cavity will be weakened. The esthetics of the restoration also will be impaired by a reflection of the underlying gold through the tooth structure above the margin of the filling. The proximal walls diverge slightly from the cavity in such a manner as to maintain maximum strength (Fig. 5). They are not undercut and therefore provide little retention for the foil. A slight cavosurface bevel is placed on the incisal and gingival margins to remove unsupported enamel and to provide greater strength to the cavosurface margins of these walls. There is no need for placement of a cavosurface bevel on the mesioproximal and distoproximal margins of the cavity since the slight flare of these walls provides the cavosurface angle with adequate strength.

PREPARATION

A standardized procedure must be followed in the development of the Class V cavity preparation and the placement of the foil if the restoration is to become economically practical for routine office use. The following points are to be observed in the preparation of the cavity:

1. A thin diamond wheel 5 to 6 mm. in diameter is used to outline the occlusal or incisal wall and to remove the bulk of

1. Ingraham, Rex. Application of sound biomechanical principles in the design of inlay, amalgam and gold foil restorations. J.A.D.A. 40:402 April 1950.

tooth structure in the central portion of the cavity. By extending this cut to the margin of the free gingiva, the height of the gingival crest is indicated on the tooth. This guide is beneficial in making the final adjustment of the cervical clamp (Fig. 6).

2. The rubber dam is prepared by punching holes to include the opposite cuspid and two or three teeth distal to the tooth to receive the restoration. The hole for the tooth to be operated on should be offset labially or buccally (Fig. 7). The rubber dam is placed on the teeth and invaginated around each tooth to prevent the saliva from seeping into the field of operation. A Ferrier 212 cervical clamp is then placed on the tooth to be operated on and the rubber dam and tissue retracted so that the gingival margin of the completed restoration will be located approximately 1 mm. below the free gingiva. The bows of the clamp are secured to the teeth with compound (Fig. 2).

3. The outline of the cavity is completed with a no. 33½ or no. 34 inverted cone bur (Fig. 8).

The first cut establishes the gingival wall 0.5 mm. above the cervical clamp. The bur is introduced in an axial direction using finger rest control to the fullest advantage. This wall must not be carried beyond the width of the arm of the cervical clamp.

The second cut establishes the distal wall by introducing the bur from the mesial direction.

The third cut establishes the mesial wall by introducing the bur from the distal direction. For the greatest speed and efficiency in preparing this cavity, these three walls should be carried to their complete extension with the initial cuts of the bur. This reduces the amount of planing necessary with hand instruments.

The fourth cut with the inverted cone bur is made by introducing the bur at right angles to the long axis of the tooth

completing the incisal extension roughly established by the diamond wheel.

4. All four walls are now refined by planing with a monangle hoe. The 10 by 4 by 8 instrument is suitable for this planing action and is used both as a chisel and a hoe (Fig. 9). The pulpal axial floor also may be planed with this instrument.

5. The undercut for retention is placed just within the dentin of the occlusal and gingival walls. This can be done most efficiently by introducing a 6½ by 2½ by 9 monangle hoe at right angles to the long axis of the tooth, then dragging the instrument sideways through these line angles to produce an undercut (Fig. 10).

6. The cavosurface finish is placed on the gingival wall of the cavity with a monangle hoe. A fine sand disk mounted on a mandrel in the contra-angle hand-piece may be used to establish the cavosurface finish of the incisal wall (Fig. 11). It is necessary to hold this disk in a fixed buccolingual position to produce a sharp definite cavobevel.

CONDENSATION

1. Mat foil is dispensed in narrow, medium and wide strips. Precaution is taken not to contaminate the foil with moisture, oil or dust. A small pair of surgical scissors is used so as to avoid crushing the mat, and the following pieces are clipped from the dispensed sections and are placed on the electric bulk annealer:

One large cantle to approximate the actual size of the cavity.

Several narrow cantles with length approximating the length of the cavity walls.

A selection of very thin wedges.

One or two large pellets of extra pliable cohesive foil.

These large pellets are placed on the annealer at this time (Fig. 12). Mat foil, unlike cohesive foil pellets, comes from the factory perfectly annealed. Further

heating of the mat foil at this time is an extra precaution against occluded moisture. Cohesive type foil is treated with ammonia gas by the manufacturer to render it noncohesive for storing. The annealing of the cohesive pellet drives this gas from the pellet, removing moisture and other occluded gases, thus restoring its cohesiveness. The electric bulk annealer should maintain a temperature of from 650°F. to 700°F. The mat foil and the cohesive foil are placed on the annealer after it has reached its maximum temperature. The optimum time for annealing before use is from 8 to 10 minutes.

2. When the foil has been annealed, one of the cantles of mat foil, cut to approximately the size of the cavity, is positioned within the cavity preparation (Fig. 13).

3. A pellet of the large extra pliable cohesive foil is then taken from the annealer and placed over the mat foil to act as a matrix (Fig. 13). Without the protection of this matrix of extra pliable cohesive foil, the mat has a tendency to flake and crumble from the cavity during condensation. The initial condensation is now carried out with hand pressure. Hatchet and hoe type parallelogram hand condensers are designed to allow the operator a maximum amount of control and finger pressure. The mat foil is driven into the retentive line and point angles and adapted against the surrounding walls. This first cantle of mat foil is further swedged into retentive line and point angles with a no. 1 condenser point by hand or by mechanical condensation (Fig. 14).

4. The strips cut to the approximate length and width of the cavity walls are now placed in position and swedged against the cavity walls with firm hand pressure (Fig. 15). Complete adaptation is attained by further condensation with a no. 2 point using either hand or mechanical pressure. Additional cantles of mat foil are added in this manner until

all surrounding marginal angles of the cavity are banked with gold foil (Fig. 16).

5. The smallest wedge-shaped fractions of annealed mat foil are now used to correct imperfections in the final banking of the cavosurface margins.

Larger cantles of mat foil may then be used to build up the center portion of the cavity until three fourths to four fifths of the cavity is filled (Fig. 17).

Mat foil should never be allowed to extend beyond the margins of the cavity. Although it is intended to bank the surrounding cavosurface margins completely as a protection against injury by a condenser point during the malleting of cohesive pellets, it should never be carried up to the final convexity of the finished surface.

6. The veneer of cohesive gold is now added to the restoration. Each pellet of foil is carefully stepped toward the surrounding cavity walls. The portion adjacent to the walls is built ahead of the center portion. Any excess foil should be removed from the margins as it appears in order to keep the outline of the cavity in view at all times. The gingival portion of the foil must be contoured to re-establish the normal confluence of the tooth surface; thus, injury to the marginal tissue during mastication is prevented. Proper gingival contour stimulates circulation and promotes good tissue tone (Fig. 18).

FINISHING

1. A pull file is ideally suited to remove excess foil and to burnish the margins of the occlusal portion of the restoration. Push files may be used to remove excess from the proximal walls and gingival margin. If the cervical clamp is quite close to the gingival margin of the cavity, the tip of a regular gold knife is used to shave the foil carefully down to the margin.

2. The next phase in refinement is carried out with the Jones Special Gold

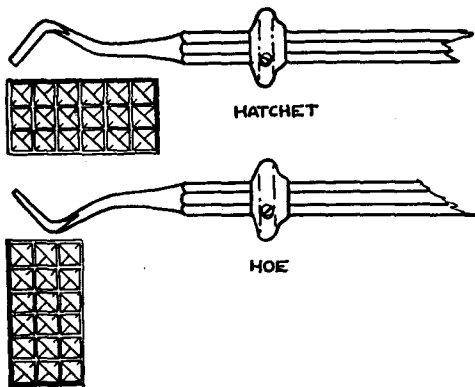


Fig. 1 • Hatchet and hoe type parallelogram condensers are used for hand condensation of mat gold foil

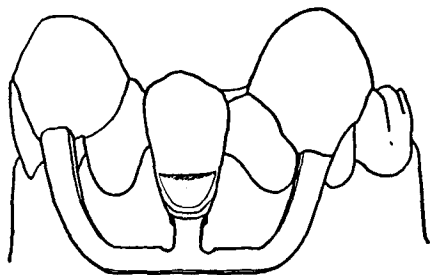


Fig. 2 • Proper application of rubber dam and proper placement of no. 212 cervical clamp (securely blocked with compound) holds gingival tissue in retracted position

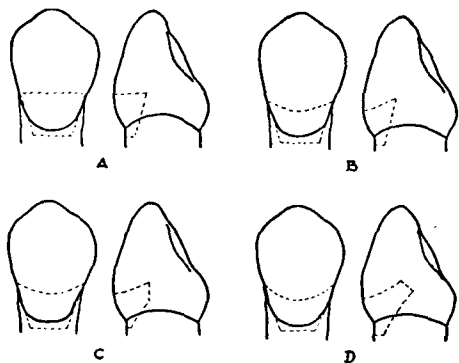


Fig. 3 • Variations in Class V outline form correspond to condition of tooth

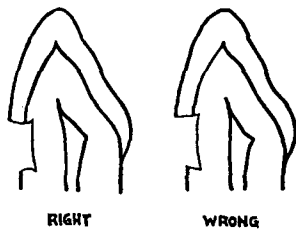


Fig. 4 • Principal retention in a Class V foil preparation is obtained by slightly accentuating gingivoaxial and occlusoaxial line angles placed just within the dentin

Fig. 5 • Complete undercutting of surrounding walls dangerously weakens enamel and cementum margins

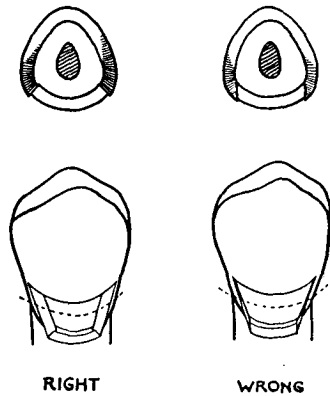


Fig. 6 • A thin diamond wheel is used to establish outline form and to remove bulk of tooth structure in central portion of cavity

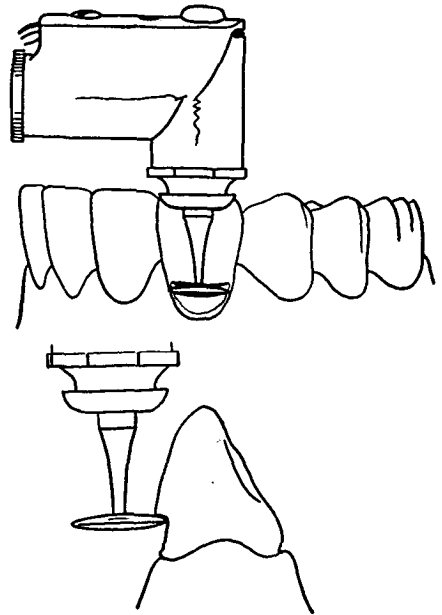
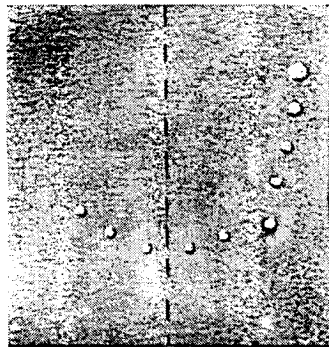


Fig. 7 • Rubber dam should be punched to include opposite cuspid and two or three teeth distal to tooth receiving the restoration to provide adequate access to the immediate field of operation



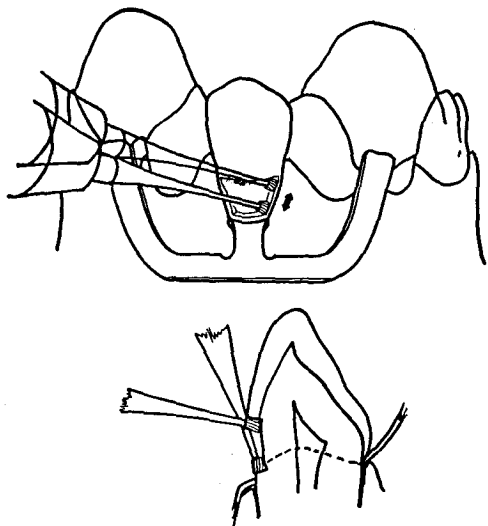


Fig. 8 • The 33½ inverted cone bur establishes final extensions of outline form

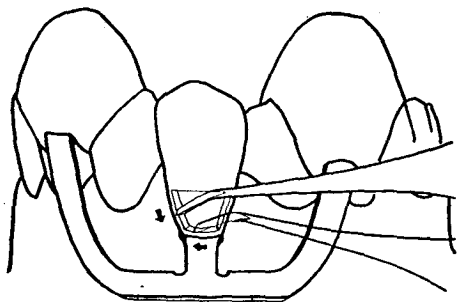


Fig. 9 • A 10-4-8 monangle instrument is used to finish the surrounding walls of the cavity

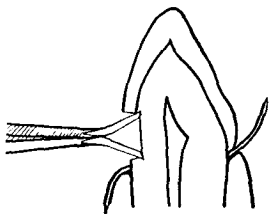


Fig. 10 • A 6½-2½-9 monangle hoe is used to establish the retentive gingivoaxial and occlusoaxial line angles within dentin

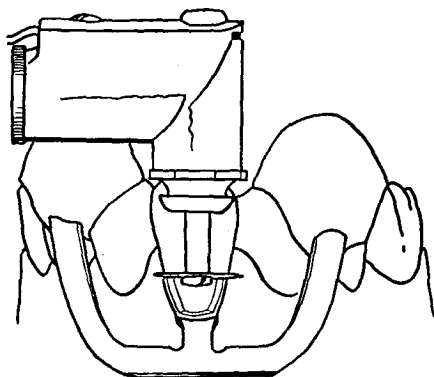


Fig. 11 • A $\frac{1}{2}$ inch fine sandpaper disk is used to define and polish the incisal or occlusal wall of the cavity

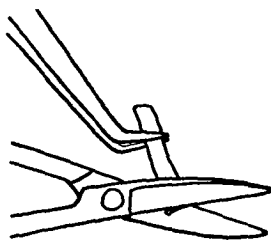
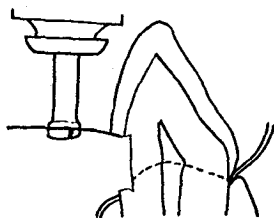
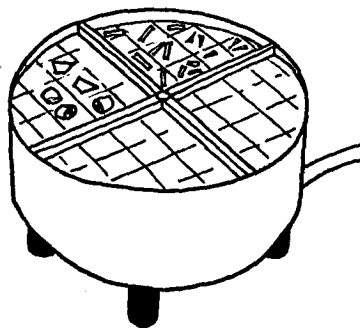


Fig. 12 • A number of cantles of assorted sizes are clipped from the ribbon of mat foil and are placed on a bulk annealer which maintains a temperature between 650° F. and 700° F.



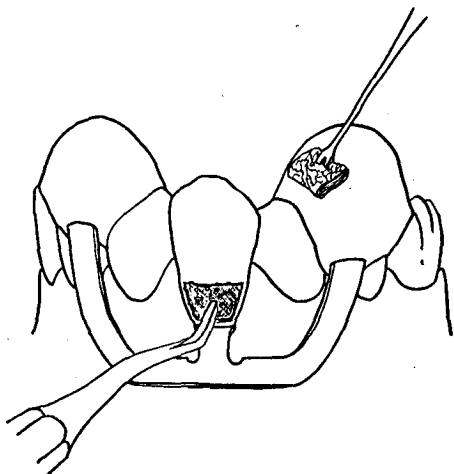


Fig. 13 • A cantle of mat foil approximating the size of the cavity is placed in position. A large pellet of extra pliable cohesive foil is placed over the cantle of mat foil to act as a matrix during condensation

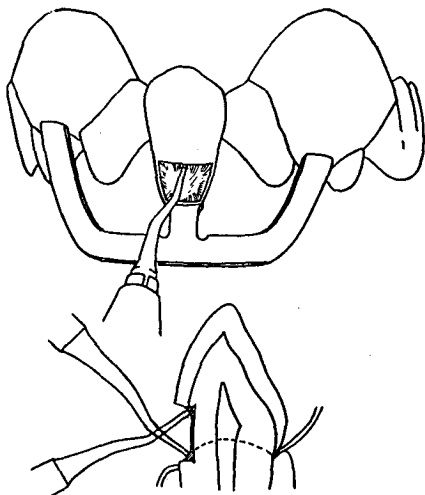


Fig. 14 • This first cantle of mat foil is further swedged into retentive portions of the cavity with a no. 1 condenser point with hand malleting or mechanical condensation

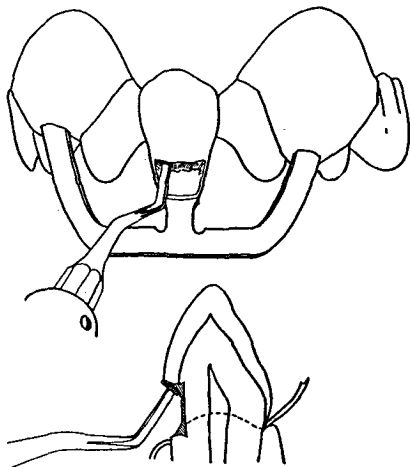


Fig. 15 • All surrounding marginal-cavosurface angles of the cavity are banked with mat foil by condensation with hand parallelogram condensers. These instruments are also used to remove any excess mat foil that may extend beyond the cavomargin of cavity

Fig. 16 • Adaptation of surrounding cavity walls and cavomargins is accomplished with no. 2 point and hand malleting or mechanical condensation

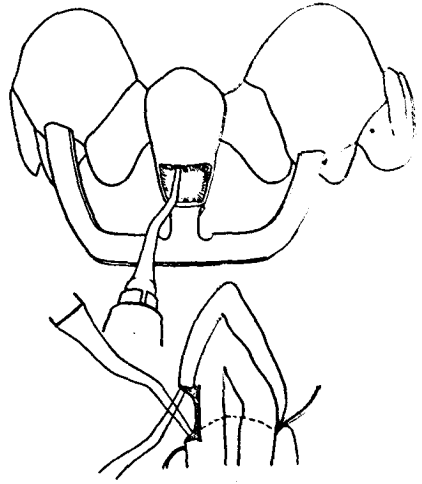


Fig. 17 • All surrounding marginal-cavo-surface angles of the cavity must be banked with mat foil

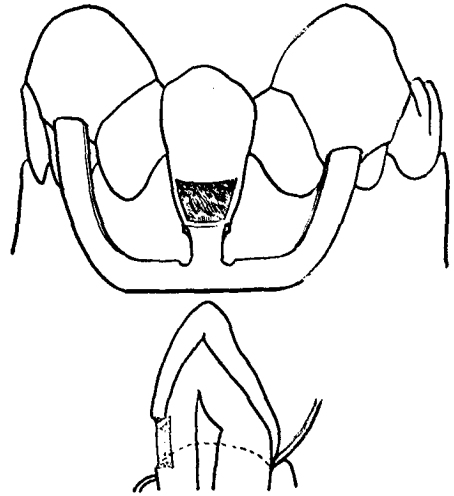
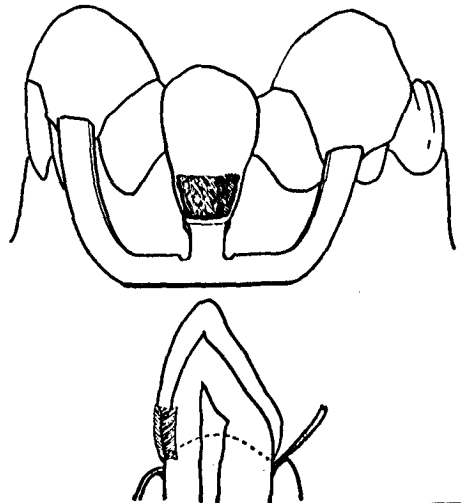


Fig. 18 • The cohesive veneer is condensed over the mat portion of the restoration and provides the final seal of the margins



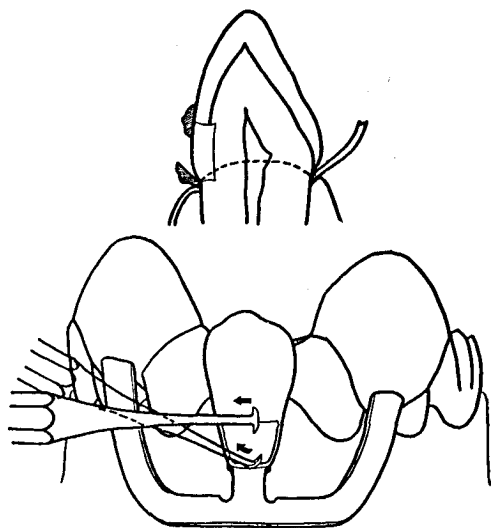


Fig. 19 • Excess foil is removed with the regular gold foil knife. Additional contouring is done with the Jones special gold foil knife

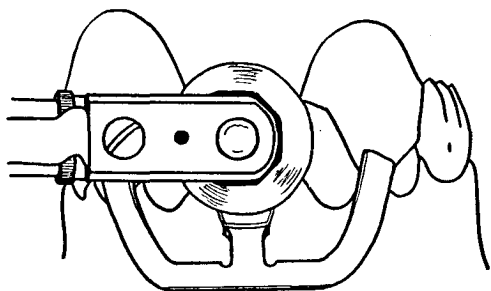


Fig. 20 • The final contour is obtained by the use of X-fine garnet disks and graduated grits of cuttle disks

Foil Knife. Any remaining excess can be removed and excessive contour reduced without damage or removal of tooth structure (Fig. 19).

3. X-fine garnet disks may be used for the final contouring of the restoration. The rubber dam should be lubricated with petroleum jelly in the immediate vicinity of the restoration to prevent the disk from tearing it and damaging the gingival tissue (Fig. 20).

4. Further disking is carried out with graduated grits of cuttle. The cuttle disk will reduce fine line scratches and pro-

vide the surface of the restoration with a satin finish (Fig. 20).

5. The final high polish is accomplished by the use of a rubber cup and pumice, followed by one of the luster agents such as chalk or true polish (Fig. 21). The cervical clamp may be raised slightly and readjusted as an extra precaution against the rubber cup touching the cementum surface of the tooth and grooving or ditching the gingival margin. Extreme precaution must be exercised by the operator when using the rubber cup.

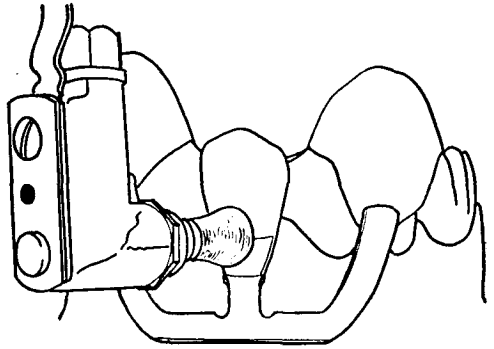
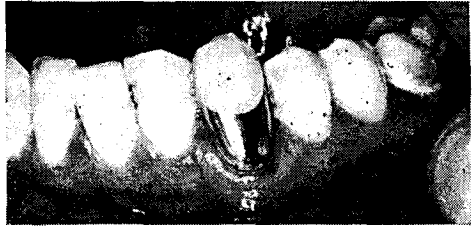


Fig. 21 • The final finish is obtained by the use of rubber cups and fine abrasive

Fig. 22 • A very large Class III-Class V restoration placed by the mat-cohesive technic. (Courtesy, Jones Gold Foil Study Club, U.S.C.)



6. The cervical clamp is removed and the gingival tissue massaged to promote circulation.

An example of a finished restoration placed by the "mat core-cohesive veneer technic" is shown in Figure 22. The veneer cohesive foil surface was condensed at a frequency of 3,600 vibrations per minute with low magnitude of blow. No postoperative symptoms were experienced by the patient after the placement of this extensive restoration.

CONCLUSION

New developments in the manipulation and condensation of gold foil have greatly

simplified Class V gold foil procedures. Utilization of a mat gold core with a veneer cohesive gold foil surface removes any necessity for long or tedious operations in the insertion of gingival restorations. Placement of the mat gold core by hand pressure and condensation of the cohesive foil surface with high frequency low magnitude vibration alleviates the objectionable factors of trauma and patient discomfort. With these advancements in technic and manipulative procedures, gold foil is the most economical, the most practical and the most ideal filling material for the restoration of gingival areas.

3731 Stocker Street

Mat gold foil with a veneer cohesive gold foil surface for Class V restorations

Koser, J. R. and Ingraham, Rex: Mat gold foil with a veneer cohesive gold foil surface for Class V restorations. J Am Dent Assoc 52:714-27, June 1956

The purpose of this paper is to offer a simplified procedure of gold foil restorations by using "mat-cohesive" technic.

Mat gold foil is highly adhesive and cohesive, and it is more readily adaptable than other types of foil. It is ideally suited for building up the internal bulk of Class V, Class I and the occlusal portion of Class II restorations. However, mat foil should not be used on the surface of restorations because it has tendency to have pit on surface. This problem can be eliminated by surfacing it with a veneer of cohesive gold foil surface.

Cavity Design

The mesial and distal wall extends to, or lie beyond, the angles of the tooth. The incisal or occlusal wall is carried to the height of the cervical contour of the crown. Retention for the foil is obtained by placing a slight undercut just within the dentin of the occlusal and gingival walls. A slight cavosurface bevel is placed on the incisal and gingival margins to remove unsupported enamel.

Condensation

The mat foil which has been cut to approximately the size of the cavity preparation is positioned within the cavity and condensed. The strip of mat foil cut to the approximately length and width of the cavity walls are now placed in position and swedged against the cavity walls with firm hand pressure. Additional cantles of mat foil are added in this manner until all surrounding marginal angles of the cavity are banked with gold foil. Then, the veneer of cohesive gold is now added to the restoration, and establish contour of restoration to produce the normal confluence of the tooth surface.

Finishing

A push files may be used to remove excess from the proximal walls and gingival margin, the tip of a regular gold knife is used to shave the foil carefully down to the margin. Follow by X-fine garnet disks and cuttle disks. The final high polish is accomplished by the use of rubber cup and pumice, followed by one of the luster agents such as chalk or true polish

Conclusion

New developments in the manipulation and condensation of gold foil have greatly simplified Class V gold foil procedures and make it the most economical, most practical, and the most ideal filling material for the restoration of gingival areas.