

GOLD FOIL *

by GERALD D. STIBBS, B.Sc., D.M.D., Vancouver, B.C.

INTRODUCTION

WHEN contemplating the preparation of a presentation on gold foil for a meeting such as this, one cannot but meditate a bit on the paradoxical position held in dentistry by gold foil.

It is one of the earliest of filling materials. There are other means of filling teeth; yet, where foil is indicated, no operative dentist of sound judgment and ability will deny that it is the restoration of unquestioned superiority. It has remained, through the years, the yardstick of operative ability and dental restorative perfection.

However, this material fell into disuse for a time, in all but a few isolated areas in the world. The reason, of course, was that too many were waiting for an easy panacea, rather than settle down to the task of acquiring an adequate technique to handle gold foil in an efficient, practical manner. As a result there have been two developments. First, the turning to other materials,—most of which have proven inadequate, even when more care is used in their manipulation than is required for foil.

The second development has been a tendency to emphasize the preventative phase of dentistry. Such efforts are laudable. Our research workers have struggled valiantly and sincerely in a fight to prevent dental caries. Some progress has been made, and undoubtedly the future holds promise of greater achievements in this field. In the meantime, however, too many of the practising members of the profession have continued to await the millennium, and to fill in the time by extracting teeth, (many of which could be made serviceable for years by proper restorative means), and then fitting out the resultant cripples with pieces of prosthetic jewelry.

It has been commonly observed that at a convention such as this, the clinics which draw the greatest crowds are those which deal with the blood and thunder, — the extractions and alveolectomies, and the beautiful, expensive, triple-suction replacements!

A pitifully few of the profession have realized that until research finds the means of preventing the onset of caries, we can and should practice the most reasonable and practical approach to the problem yet known. That solution is the arresting of decay by the careful restoration of lost tooth structure in the first stages of the destructive process by means of the most permanent filling material at our disposal. And what is that material? The previously mentioned yardstick of perfection—Gold Foil.

A perusal of the program shows that the committees in charge have endeavoured to produce a very complete and well-rounded panoramic view of the many phases of modern dentistry. They are to be commended for seeing fit to give operative dentistry a prominent place in their plans. Yet, is it flattering to us as a profession that our desires should be so accurately interpreted, that out of twenty different group clinics only one is required on gold foil?

However, a little light is better than none, especially in the dark. There is hope for a more widespread revival of sound operative procedure. Whereas, in the past, many meetings have had no evidence of gold foil on their programs, today no really progressive program committee considers its lineup of clinics complete unless some place is given to foil. Speed the day when, as a matter of course, they will present to us not only one paper on gold foil, but what is of more value, groups of chair clinics, showing actual

* Presented before the National Convention of Canadian Dentists, Toronto, Ontario, May 28, 1946.

cavity preparations and methods of manipulating the material.

The disfavour accorded foil for a time was a natural reaction to the mistaken enthusiasm which engendered an era of sittings of many hours to insert huge fillings with the automatic mallet and which resulted in premature aging of the operator, premature death of the pulp, and a prayer for delivery by the patient.

However, recent leaders in operative dentistry have diligently refined gold foil technique, and have determined the common sense indications and contra-indications for its use. As a consequence, the operation has been standardized so as to make it one of comparative ease for the patient, freedom from hazard for the tooth, and a definite pleasure and stimulus for the operator.

It is my hope to bring to your attention some of these refinements in procedure. Many of you know of them; some are using them. Perhaps you will bear with the review while the few others hear of them, either for the first time, or from a different viewpoint than before. It must be confessed that the information is not offered as being original in any sense. Rather, it has been absorbed over a period of some ten years spent in active gold foil study club participation, and to the leaders of the study clubs sincere gratitude is acknowledged.

The points to be brought out are principles and details of technique as being taught for the past twenty-five years by Dr. W. I. Ferrier of Seattle, and as currently reviewed and emphasized in the Vancouver Ferrier Study Club by its instructor, Dr. G. A. Ellsperman of Bellingham, Washington.

STUDY CLUBS

Let me here say a word in favour of study clubs. It is only by group study and constant criticism that one's proficiency in technique develops. From a paper or discussion such as this, some points are picked up; the

occasional operator will absorb enough of a technique to utilize it 'in toto' in his practice; but the most good is achieved, and the finer points are learned only by months and years of consistent study club participation. As a case in point, Dr. Ferrier's original group in Seattle has been meeting regularly each month for twenty-five years. The members would not miss a meeting for any reason short of a broken leg, and they each realize that they are learning all the time. They know, too, that their practices are of the calibre they are as a direct result of their membership in a gold foil study club.

One cannot but feel that it would be of unlimited value for more groups of sincerely interested individuals to organize foil study clubs under competent guidance, making the entrance requirements such that only those who mean business will be admitted, and then stick to it and experience the thrill and joy of feeling one's ability and judgment develop, no matter from what degree of accomplishment the effort commences. The acquisition of dexterity in the use of gold foil is at once challenging and stimulating.

PRE-REQUISITES

In entering upon a consideration of gold foil, one of the first pre-requisites is the rubber dam. In past years the rubber dam has been subjected to all the indignities and negligence usually accorded an ugly duckling. Some men even boast of having no dam in their offices. As Dr. Prime of Omaha has said—"they might just as well boast of not washing their hands." For some reason the technique of application has been made unnecessarily cumbersome and time consuming, and in some cases even damaging to the very tissues it was supposed to protect. In actual fact the application of a rubber dam should be a procedure as effortless and natural as putting on your tie. It should take only two or three minutes to accomplish, including the placing of necessary clamps and block-

ing them with compound. The value of the dam and the technique of application have been well covered previously in the literature. Two articles I would particularly recommend that you re-read are the ones by Dr. H. M. Cline in the *Journal of the Canadian Dental Association*, January 1940, and by Dr. G. A. Ellsperman in the June 1944 issue of the same publication. General principles to be pointed out are to standardize the placement as much as possible in each case. Your nurse then knows what to expect, a closer cooperation will be developed, and the time element will be practically eliminated as a factor in the operative procedure. Another cardinal principle is that it is never necessary to ligate teeth to place or retain a rubber dam. That little stunt is one of the finest ways to assure the patient of an early visit to a periodontist. It might be said that inaugurating the daily use of the rubber dam is the beginning of wisdom in operative dentistry.

The second of the pre-requisites to a gold foil operation is, of course, proper armamentarium. Under this heading would be included instruments and gold foil. In respect to instruments, finely-made accurate hand instruments are a distinct advantage. Such are now available. Remember that instruments must be kept keenly sharpened. It may be necessary to sharpen an instrument one or more times during the preparation of a cavity. Consider, too, that only about one millimeter of the blade of an instrument is properly tempered, and that with sharpening the effective life of an instrument is soon expended. However, they are reasonable in price and should be discarded or sent in for re-cutting as soon as their best purpose has been served. The best of operators would be seriously handicapped with dull, worn-out instruments; therefore, the average one of us is deliberately practising the "hard way" if he keeps sharpening his instruments right up to the handle. Burs are, of course, included with instruments. Use fine, sharp, true burs and discard them or

set them aside for less exacting work after the first use. Get fun out of your foils,—and one of the best ways to do that is to work with tools in the best of condition.

For the placing of the gold, hand instruments are used. Condensation is accomplished by a combination of hand pressure by the operator, augmented by blows from a mallet in the hand of the assistant. A rhythmic teamwork is acquired so that there are two mallet blows for each placing or stepping of the plugger. The plugger point is moved systematically half of its diameter each time, condensing the gold in regular rows. This avoids the occurrence of soft spots in the filling and also makes the gold flow progressively in the direction in which the plugger is inclined.

There are a few locations in which the mallet and hand pluggers are not the easiest means for gold condensation. These areas include gingival cavities on lingual surfaces of molars, lingual pits in upper anteriors, and occlusal pits and fissures of lower molars. In these locations the right angle attachment of the Hollenback pneumatic condenser gives direct access to the cavity.

The gold used is No. 4 non-cohesive foil, obtained in book form and prepared by the assistant during spare moments. The advantages of so preparing it are that the pellets are of known size and bulk, and the cylinders, which are used in the non-cohesive state, are far superior to any machine-made forms at present available. The 4-inch square sheet of gold is cut into 1/8ths, 1/16ths, 1/32nds, and 1/128ths, and rolled into pellets for use in the cohesive state; sheets are also cut into 1/2's, 1/4's, 1/8ths, and 1/16ths, and then folded and rolled on a jeweller's broach into cylinders for non-cohesive gold. The non-cohesive gold pellet is rendered cohesive by heating it to a red colour over an alcohol flame.

The preparation of the various classes of cavities and the filling of them has been well and thoroughly

written by Dr. Ferrier in the Journal of the American Dental Association in April 1934, March 1936, and May 1941; by Dr. G. A. Ellsperman in the March 1940 issue; and by Dr. R. E. Hampson in the July 1942 issue of the same publication. It is well worth your while to read and reread these excellent papers. For the benefit of those who may not have access to them, permit me to summarize the essentials for each of the major classes of cavity.

CLASS 5 CAVITIES

The first class of cavity to be considered is the Class 5 or that occurring in the gingival third of the tooth. It is difficult to understand how the profession can be satisfied with any other filling material than gold foil in these areas, unless it be for the comparatively few cavities which, for aesthetic reasons, demand a compromise with perfection by placing porcelain inlays.

Most of you are acquainted with the preparation for this type of dental defect whether it be erosive or carious in origin. The rubber dam is applied, and a well designed gingival clamp such as the Ferrier No. 212 is placed, and blocked to position with modelling compound (Fig. 1). It is never necessary to cut or reflect the gingival tissue for access to these cavities. The bow of the clamp will carry the soft tissue out of the way and protect it from injury during the operation. In

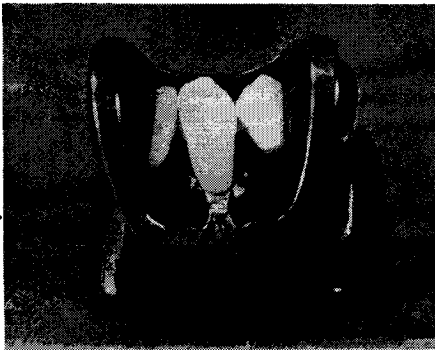


FIG. 1

Ferrier gingival clamp in position and blocked with modelling compound.

the large majority of these areas of erosion or caries, observation will show the cavity automatically outlined by the defect. (Fig. 2) In general, the gingival and occlusal or incisal walls

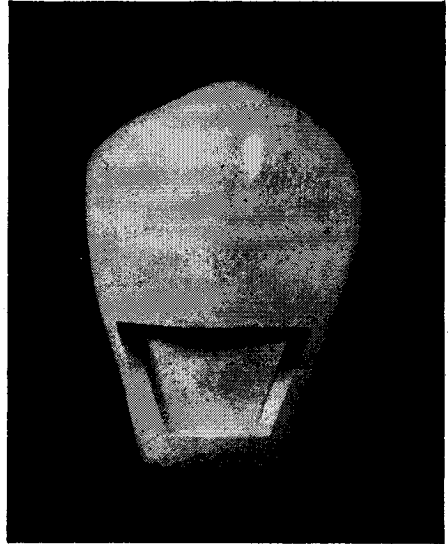


FIG. 2

Typical Class 5 cavity preparation, showing gingival and occlusal walls slightly undercut, and mesial and distal walls flared.

are cut straight and parallel with the occlusal plane; the mesial and distal walls are also cut straight, parallel with the corresponding line angles of the tooth, and they meet the axial wall at a slightly obtuse angle. The four circumferential walls meet each other in sharp line angles. The walls are so placed that these line angles of the completed restoration extend somewhat beyond the eroded or decayed area, and lie under the gingival tissue. The only portion of the outline which remains in view, then, is the straight incisal or occlusal cavo-surface line angle. Aesthetics are thus much improved. Retention is gained between the gingival and occlusal walls; the outward flare of the mesial and distal walls protects an otherwise potentially weak area from possible fracture from the wedging action of the gold.

The outline form is obtained by the use of a small inverted cone bur, held

so that the end of the bur establishes the mesial, distal and gingival walls, and the side of the bur is used to cut the occlusal wall. The walls and angles are straightened and trued with a small hoe, followed by a Wedelstadt chisel, and in so doing the cavo-surface margins automatically receive a very slight bevel; the axial wall is flattened and smoothed with the Wedelstadt chisel and the preparation is complete.

The filling of the cavity is accomplished by lining the walls with non-cohesive cylinders. They are placed one to a wall, on end in the cavity. First the mesial and distal walls are covered; these two cylinders are locked in place by the third placed against the gingival wall; the fourth is then wedged against the occlusal wall. All are condensed by hand pressure with parallelogram pluggers. The cohesive foil is then started along the axio-gingival line angle and is retained with a holding instrument until sufficient bulk is obtained to lock it into the occlusal wall. The foil is built up saucer fashion against the four walls; the plugger is stepped in rows progressing from the centre of the cavity toward the margins, gradually pinching off the excess non-cohesive gold at the margins. Contour is then completed.

Finishing is accomplished chiefly with files and knife, then with fine small discs lightly lubricated with vaseline, and finally the surface is brought to a high polish on lowers and posteriors, and to a satin finish on upper anteriors with a polishing powder. A word of caution,—if the gingival margin extends gingivally of the cemento-enamel junction, care must be exercised in finishing not to ditch the cementum. Also, keep the restoration cool during the discing and polishing to avoid what has been termed 'barbecuing the pulp.' After the dam is removed, transilluminate the gingival tissues to be sure that no trimmings or polishing powder still remain under the gum line.

These gingival foils when placed

are a real thrill to patient, nurse and operator. There is a sense of something really worthwhile having been done. The greater portion of such a foil is soon covered by the gum tissue, gingivitis is not encountered, and recurrence of decay is at a minimum unless future gum recession should extend beyond the gingival margin of the restoration.

CLASS 3 CAVITIES

The class 3 cavity or that occurring in the proximal surface of the anterior teeth is the next to be considered. Here again is a strong indication for foil, especially in cases of incipient decay. What other material can be placed in one appointment that will restore proximal contour, re-establish contact and protect the tooth as well and as long as gold foil? In larger cavities, especially those on the mesial surfaces of the teeth, the demands of aesthetics will many times contraindicate the use of foil.

One of the finest areas of this type for foil is the distal surface of the cuspid, either upper or lower. By utilizing the modified preparation as advocated by Ferrier, an operation which was formerly an ordeal with foil, and consequently usually resulted in the placement of an inlay and many times

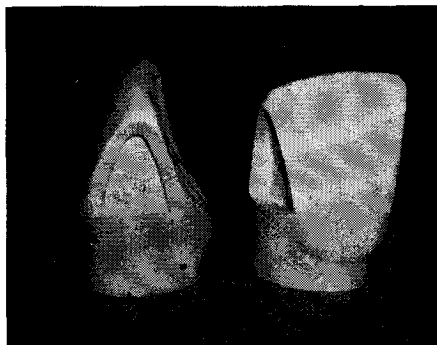


FIG. 3

Typical Class 3 foil cavity in upper central incisor, showing straight gingival wall meeting lingual wall in a definite angle and shoulder; the labial outline in harmony with the tooth contour; and the retention solely between the gingival wall and the incisal angle.

even a silicate cement, has now become as relatively simple to complete as a class 5.

Without going into detail, (Fig. 3) the typical class 3 cavity is cut with a straight gingival wall which meets the lingual wall in a sharp definite angle and shoulder, which greatly facilitates the placement of the foil. The labial outline is cut parallel to the lobe of the tooth and thus is in harmony. Retention is between the gingival wall and the rounded incisal point angle; the labio-axial and linguo-axial line angles are obtuse. The axial wall is flat.

There are three indications for variations in the typical outline. The first is in the distal surface of upper lateral incisors which have a definitely rounded disto-incisal angle. Here the labial outline is cut straight from the incisal cavo-surface to the labio-gingival margin, and is parallel with the distal lobe of the tooth throughout. The reason for this variation is an improvement in aesthetics, as well as providing a direct incisal approach for the placing and condensing of the foil.

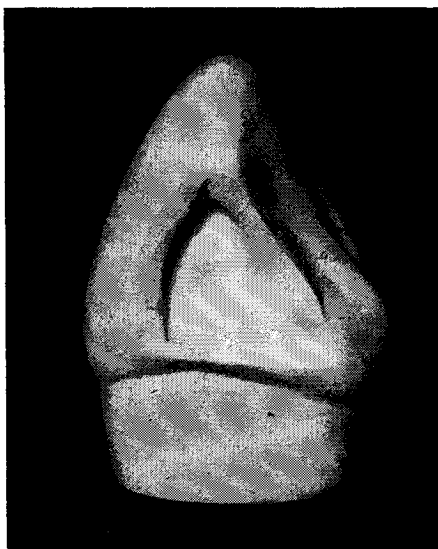


FIG. 4

Cavity form for the distal of the upper cuspid. The labial and lingual outlines are straight for greater access, and the labial and lingual walls are well boxed.

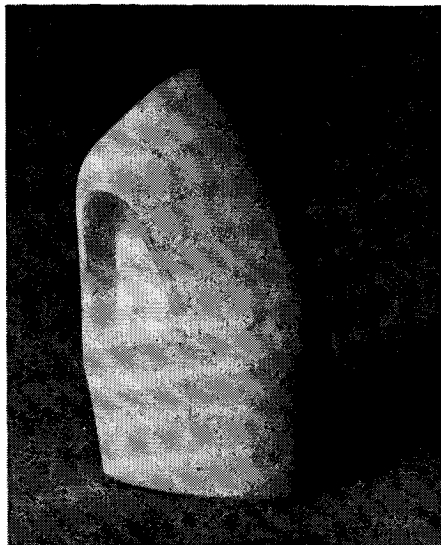


FIG. 5

Cavity preparation for the distal surface of the lower cuspid. The lingual wall is left standing in these lower anterior teeth to support the incisal angle.

The second variation occurs in the distal surface of the upper cuspid, and the reason this time also, is greater access to the cavity for filling (Fig. 4). The change, which becomes the normal in this preparation, is that the labial and lingual outlines are straight from the incisal cavo-surface margin to the labio-gingival and the linguo-gingival margins. This permits more ease in placing and condensing foil into the broad labio-lingual dimension which occurs in these cavities, because a direct approach is afforded.

The third variation is the preparation used for class 3 cavities in the lower six anterior teeth (Fig. 5). The labial outline is fundamentally the same as for the typical preparation, except that it can be held in so that gold need not be visible. The chief modification is that the lingual wall is left standing to give greater strength to the incisal angle of the tooth. The lingual margin is extended only sufficiently to secure one that can be properly finished. All gold is placed from the labial. As long as care is

taken to properly condense the gold along this lingual wall, there will not be recurrence of decay by reason of the limited extension.

The filling of the class 3 cavity is accomplished by the use of cohesive foil entirely. It is started by placing and condensing a small pellet in the linguo-gingival angle. Successive pellets are added to secure some bulk (Fig. 6). This portion is securely held, while the foil is carried along the axio-gingival angle to the labio-gingival angle. It is tied in to the labio-gingival point angle with a few small pellets, condensed with plugger force directly into this angle (Fig. 7). It should then be safe to discard the holding instrument.

The next step is to complete the coverage of the linguo-gingival shoulder, using a plugger from the incisal

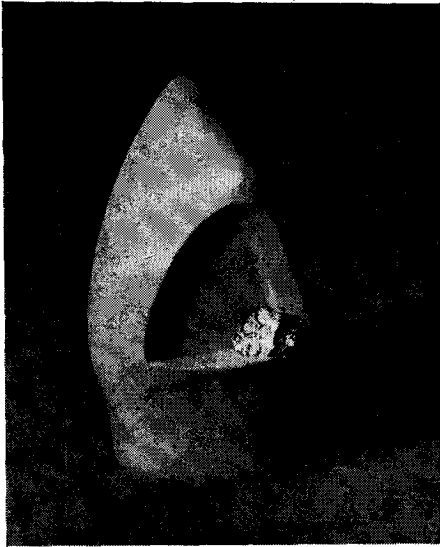

FIG. 6

Placing and condensing foil in the Class 3 cavity. First pellets are placed in the linguo-gingival angle.

directly along the lingual margin. This is the area where many foils are defective and care should be taken to adequately condense the foil at this

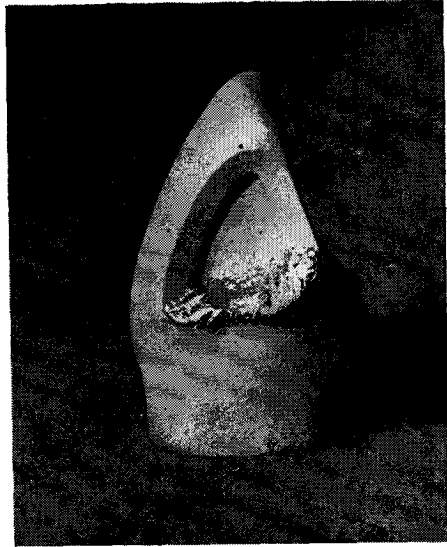


FIG. 7

Foil locked into labio-gingival angle; gingival wall and lingual shoulder covered.

point. If it is not done now, it is not easy to do at any later stage.

From this point on, most of the gold is added from the labial. The gingival wall is covered and the gold is built up toward the incisal angle along the whole labio-lingual width of the axial wall, keeping the lingual portion somewhat in advance of the labial portion (Fig. 8). When the incisal third of the lingual wall is reached, small pellets are condensed into the incisal angle. These are then joined to the main body of foil by the addition of more foil (Fig. 9).

A properly designed separator is then placed and blocked with compound, and the teeth slightly separated. The step which Ferrier calls 'making the turn' is then executed. There is a change in direction of plugger force. The holding instrument is now used to support the filling gingivally, while gold is added against the incisal third of the lingual wall, and this portion and the incisal cavo-surface are covered to excess with force applied incisally (Fig. 10). The balance of the bulk and contour is then added, using a plugger

force directed axio-gingivally (Fig. 11).

A variation from the above outline of procedure is that in the lower four incisors, a separator is placed before the cavity is prepared. It stabilizes these small teeth, and distributes over several teeth the force of the preparation of the cavity as well as that exerted in the condensation of the gold. Resultant soreness of the periodontal membrane is thus avoided.

Class 3 foils are finished by contouring to form and reducing excess chiefly with knives and files, and long linen strips of various grits (Fig. 12). Cool air is played on the tooth during the

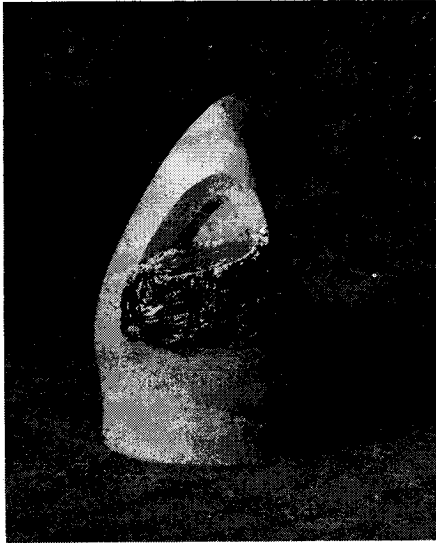

FIG. 8

Gold built up along whole labio-lingual width of the cavity, keeping the lingual somewhat ahead of the labial portion.

use of the strips. A satin finish, obtained by the use of a worn out extra fine cuttle strip, is most desirable for foil in this location. The restoration, with its outline in harmony with the shape of the tooth, is made even less conspicuous by this means. After removal of the dam the occlusion should be observed for any interference from an over-contouring of the lingual marginal ridge.

CLASS 2 CAVITIES

Incipient areas of decay in the proximal surfaces of bicuspid and the

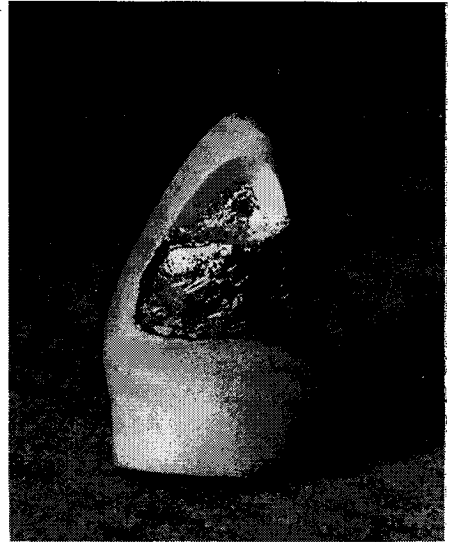


FIG. 9

Small pellets condensed into incisal angle and joined to the main body of foil.

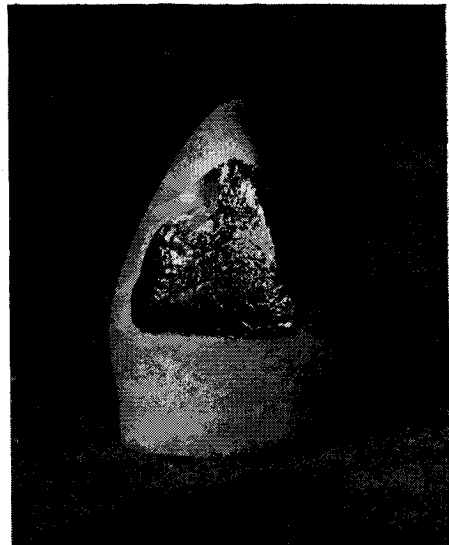


FIG. 10

"Making the turn". Foil condensed along the incisal third of lingual wall, and the incisal wall, with plugger force directed incisally.

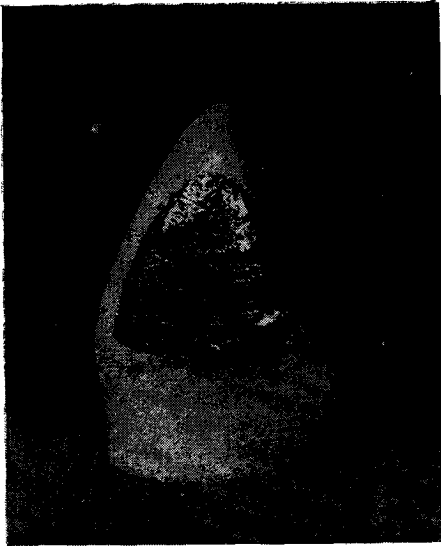


FIG. 11
Foil completely placed, to slight excess.




FIG. 12
Finished operation. Foil brought to satin finish rather than high gloss.

mesial surfaces of molars are strong indications for restoration with gold foil. The advantages of foil are many here. The peer of filling materials can be placed in these locations in one appointment in a time equivalent to

or less than that required for a good inlay. The chief advantage is that, keeping in mind the shape of these teeth, and the requirements of cavity preparation from the standpoint of extension, resistance, retention and convenience, a cavity prepared for the reception of gold foil is the most saving of tooth structure, and offers greater pulp protection and less impairment of strength of the tooth than is possible for any other material. In this,

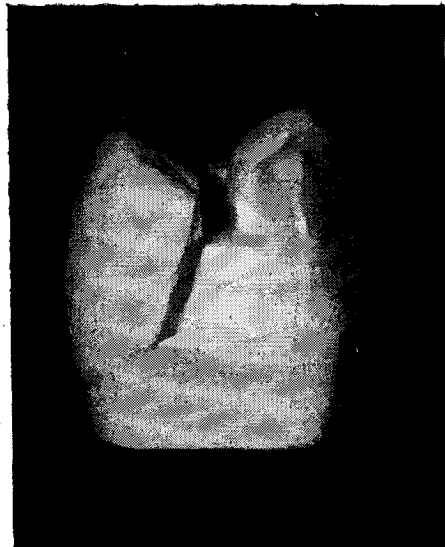


FIG. 13
Typical Class 2 foil cavity preparation in upper bicuspid. Proximal walls converge occlusally, saving tooth structure; buccal and lingual walls are not undercut; occlusal step narrow, yet adequate for strength of filling.

as in other types of cavities, the greater the extent of the decay, the less the indication for gold foil.

In the class 2 foil cavity there are the typical preparation and filling procedure, and two variations. For the typical preparation the cutting is conservative. (Fig 13). The proximal outline is formed, by establishing the bucco-gingival and linguo-gingival angles for prevention of recurrence of decay and then holding in the extension of the buccal and lingual walls to give just sufficient clearance to bring them

to a self-cleansing area. This will automatically make the bucco-lingual width of the box portion of the cavity much narrower at the occlusal than at the gingival. The bucco-axial and linguo-axial line angles are obtuse. Undercutting of these walls is not necessary for retention. The gingival wall may be slightly undercut, but that is not necessary either. The axial wall is flat. Line angles and point angles are definite and sharp.

Retention for this cavity is obtained in the occlusal step. Yet it is also cut very conservatively. The pulpal wall is flat. The depth of the step will be determined by the thickness of the enamel, the occlusal stress, and the depth of the sulci. Its width is held in so as to give just a nice proportioning to the cavity. On the average, in a bicuspid it will be not more than one millimeter, which is established by a hoe having a blade of that width. The bucco-pulpal and linguo-pulpal angles are right angles except in their middle third where they are obtuse. The terminal end of the occlusal step is slightly dovetailed, and here, too, walls are flat and angles definite. The bucco-occlusal wall blends into the buccal wall of the proximal portion in a reverse curve which opens the throat of the cavity and so permits greater access in filling and an increased bulk of gold for strength. Final planing of the occlusal cavo-surface margins is made with instruments used parallel to the occlusal surface of the tooth. This avoids a cleavage of the enamel rods and a resultant over-cutting of the cavity.

The filling of this class 2 cavity is simplified by using non-cohesive gold for the bulk of the proximal portion, and cohesive gold for the remainder of the cavity. Three non-cohesive cylinders are used. Their size is estimated so that when the three are placed and condensed the cavity will be filled almost to the level of the occlusal step. They are carried to position with the end of the cylinder against the axial wall. One is forced against the buccal

wall, one against the lingual, and the third wedged between the first two. They are thoroughly condensed with a large faced plugger, and the hand mallet. The cohesive foil is then started at the terminal end of the occlusal step. It is gradually built up and extended along the pulpal wall, out on to the non-cohesive gold. Contour is completed. The condensation of the gold will automatically wedge the teeth apart sufficiently to give bulk for proper contact in the finished

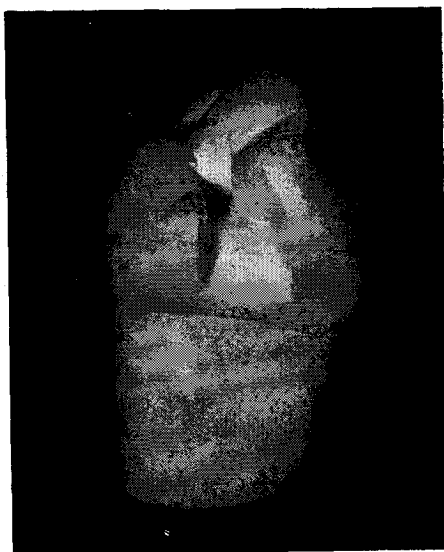

FIG. 14

Cavity preparation for distal surface of lower first bicuspid. Occlusal step does not cross transverse ridge. Pulpal wall sloping lingually protects buccal horn of pulp.

restoration without placing a mechanical separator. Final condensation of the proximal gold is done with soft-foil condensers and a smooth swedging plugger to burnish the area of the contact point.

The foil is finished down by cutting the excess non-cohesive gold from the gingival margin with a knife, and passing a strip through the embrasure to establish the gingival contour. The occlusal contour is worked out with small mounted stones, burs and a cleoid. The contact area and proximal

portion are then finished by placing a separator, and reducing the excess gold with a knife, files and strips. A high polish is given the restoration, using pumice followed by a final finish powder. After the dam is removed, occlusion is checked.

The variations for the class 2 cavity occur in the lower first bicuspid, due to the anatomy of this tooth, and to its position in the arch. If it is a distal cavity, or a mesial cavity which requires an occlusal step, that step is extended to a point just short of the transverse ridge, which retains the structural integrity of the tooth (Fig. 14). The pulpal wall is sloped lingually, so as to make the step even in depth bucco-lingually, and so protect the buccal horn of the pulp.

The second variation is one reserved solely for the mesial surface of the lower first bicuspid. Inasmuch as this surface is not subject to occlusal stress, but is definitely subject to aesthetic demands, a cavity of minimal extension is most suitable. The separator is applied and blocked before starting the preparation. The cavity is a simple proximal cavity, with no occlusal step (Fig. 15). Retention is obtained by undercutting the buccal and lingual dentinal walls, but not the enamel at the occlusal opening of the cavity. The buccal and lingual walls converge markedly occlusally so that an absolute minimum of gold is visible in the finished restoration (Fig. 16). In filling this cavity, it is best as a rule to use only cohesive gold.

CLASS 1 CAVITIES

The final class of cavities to be discussed are those occurring in pits and fissures of the teeth. This would include the occlusal surfaces of bicuspids and molars, and lingual surfaces of incisors. These cavities are best treated when filled with gold foil. The procedure is simple; there is a minimum of tooth cutting; young patients will be particularly proud of their dentistry, and deservedly so. These

small restorations constitute one of the finest means of educating patients to the effectiveness of fine dental procedures. It would be difficult to foist off any inferior type of restoration upon a patient who has had the pleasant service of one or more of these small gold foils since childhood.

The technique for the management of this class of cavity is the most eas-

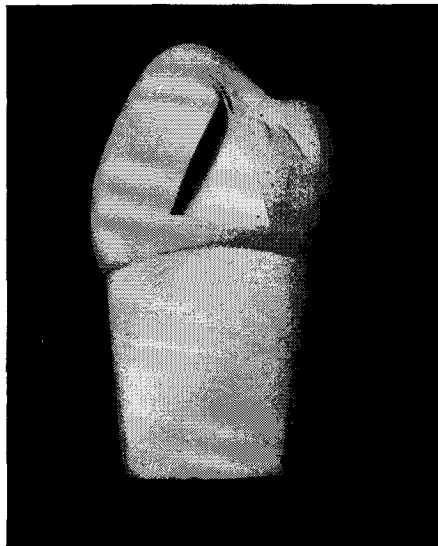


FIG. 15

Cavity preparation for the mesial surface of lower first bicuspid. No occlusal step; buccal and lingual walls converge markedly occlusally and are undercut to provide retention.

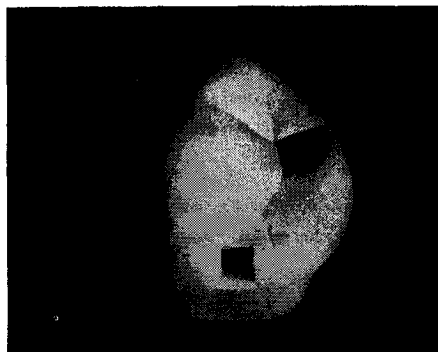


FIG. 16

Occlusal view of cavity shown in Fig. 15. A minimum of gold is visible in the finished restoration, yet access is sufficient for filling.

ily mastered, but care must be exercised. The cavities are kept very small (Fig. 17). Most of the preparation is made with very small fissure burs; then the walls are planed and slightly bevelled with instruments cutting parallel with the surface of the tooth, rather than at right angles to it. The cavities are filled with cohesive gold unless they are large. In the latter case the walls are lined with non-cohesive cylinders pressed thin, and the remainder of the cavity filled with cohesive pellets. The use of the Hollenback right angle pneumatic condenser, especially for lowers, makes the filling of these cavities very easy.

Finishing is accomplished by dressing down the gold with fine stones, burs, and a cleoid, and then polishing with pumice and a polishing powder.

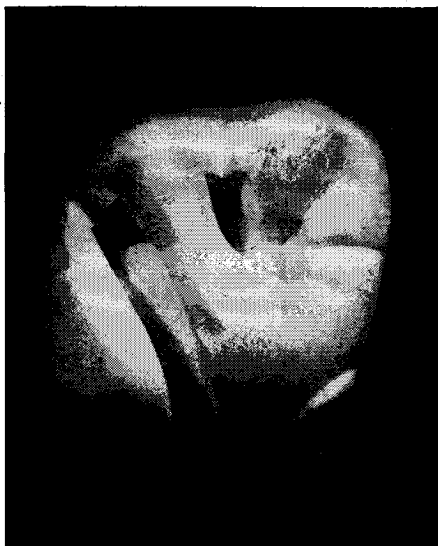

FIG. 17

Class 1 cavity preparation in upper molar.
Cutting is as conservative as possible.

These small delicate restorations make the operating day really worthwhile.

CONCLUSION

It is hoped that in reviewing the present day refinements and simplification of gold foil technique, there may be a more acute realization of the obligation of the operative dentist, and of the pleasure that awaits him when he directs his efforts to the increased use of gold foil, which, to date, still most nearly fulfills the requirements for the ideal filling material.

The time and money spent in acquiring dexterity in the use of gold foil will pay greater dividends than a similar expenditure in any other phase of dentistry. The returns are apparent not only in the improvement in the type of practice and in the monetary reward, but what is more important—in the satisfaction and enjoyment of performing the finest operation possible in the practice of our profession.

BIBLIOGRAPHY OR REFERENCES

- Cline, H. M., Observations in Operative Dentistry, J.C.D.A. 6:3, Jan. '40.
- Ellsperman, G. A., Refinement of the Gold Foil Restoration, J.A.D.A. 27:342, Mar. '40; Review of Operative Procedures, J.C.D.A. 10:253, June '44.
- Ferrier, W. I., Clinical Observations in Areas of Erosion, and Their Restoration, J.A.D.A. 20:1150, July '33; Treatment of Proximal Cavities in Anterior Teeth with Gold Foil, J.A.D.A. 21:571, April '34; Treatment of Cavities with Gold Foil, J.A.D.A. 23:355, Mar. '36; Use of Gold Foil in General Practice, J.A.D.A. 28:691, May '41.
- Hampson, R. E., Gold Foil Restorations for Incipient Decay, J.A.D.A. 29:1141, July '42.
- Jones, E. M., Treatment of Caries in Anterior Teeth with Gold Foil, J.A.D.A. 26:532, April '39.
- Prime, J. M., Foil vs. Inlay, J.A.D.A. 18:1009, June '31; Gold Foil, J.A.D.A. 18:1477, Aug. '31; The Rationale of Gold Foil, Cosmos 76:745, July '34; Is Operative Dentistry Failing? J.A.D.A. 23:47, Jan. '36.
- 1523 Medical-Dental Building.

Reprinted from April 1947 Issue

THE JOURNAL OF THE CANADIAN DENTAL ASSOCIATION